

Bob Boyce's un-requested VeriChip and associated tumor removed

Boyce finally had the second VeriChip implant removed yesterday along with the associated tumor. This time the surgical staff documented the implant with photos, and the surgeon placed the "foreign body" in a specimen container and sealed it to establish chain of custody evidence.

by [Sterling D. Allan](#)
Pure Energy Systems News
Copyright © 2010

Last year we reported that Bob Boyce, the highly-revered inventor of [ultra-efficient electrolysis](#) systems and of a [self-charging battery circuit](#) (harnessing energy from the environment, possibly from zero point energy), had contracted terminal cancer and that the originating point was a VeriChip microchip that someone implanted in his right shoulder without his knowledge or permission.

He had a chip removed, but it turned out that another chip was still in there, implanted deeper, as confirmed by an [X-ray](#).

He's lived with that one for a year, but finally had it removed yesterday at the [Fannin Regional Hospital](#) in Blue Ridge, Georgia.

The Fannin surgical staff took photos as the chip was removed from the tissue and placed in a specimen container, labeled "foreign body", and sealed by the surgeon. The blue color of the tissue is from a dye that was injected to mark cancerous cells.

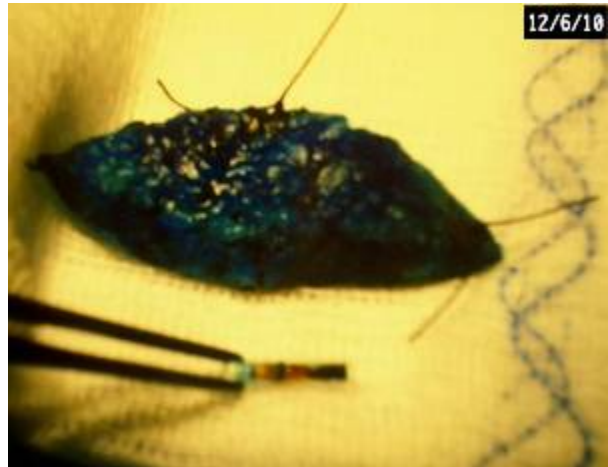
Such chips have been documented to sometimes instigate tumors where they are implanted ([ref](#)), as was the case with Boyce ([ref](#)).

Boyce [posted photos](#) of the process on his [website](#), along with the comment:

Some have said that this VeriChip was a figment of my imagination. Well, this "imaginary" VeriChip removal was documented on film by surgical staff.

The first time Boyce noticed what turned out to be the first of two chips was in early April, 2009 when he was working with a former associate, [Bob Potchen](#), of Precombustion Technologies Inc. (PTI), now "[The Cell](#)", who he first met in July of 2008. Potchen, formerly with NSA, was implementing Boyce's hydroxy gas booster technology into a product to take to market. Their relationship had been growing tense, and Boyce was preparing to depart.

After drinking a "refreshment" drink Potchen provided, Boyce had fallen asleep at a desk at PTI's office, pulling an all-nighter. When he awoke, his right shoulder felt like it had been numbed; and when he rubbed it, he noticed a small, hard lump there. Having recently had some benign skin cancer removed, he assumed it was just another tumor, and thought no more of it, until the skin turned red and his shoulder became very sore many months later.



A second [VeriChip](#) microchip implant was removed yesterday from [Bob Boyce](#)'s shoulder, which was placed there without his knowledge or consent. The blue color is from a dye that pinpoints cancerous cells, which are not uncommon to form along with VeriChip implants ([ref](#)).



The VeriChip "foreign body" was placed in a specimen container and sealed by the surgeon.



Close-up of a VeriChip

Back at his own lab, he noticed that his shoulder was "transmitting" RF radiation. Then, when he had the tumor that formed there removed, he looked at the small-grain-of-rice-sized microchip before the doctor took the tissue away to be examined by pathology. He then researched various companies that manufacture implantable microchips, and he saw that the chip that had been removed from his shoulder matched the chip design by [VeriChip](#). In particular, there is a thin, white rubber-like coating on one end that the tissue grows to so the chip won't migrate. The pathology report did not mention the chip.

Due to the politics of the situation, Boyce has had a hard time finding a surgeon to remove the chip and document its removal. This time around, Boyce wanted to make sure there was proper legal "chain of custody" when the second chip was removed, as certified by the surgeon when placed in a specimen container, which was sealed, labeled, dated, and signed by the surgeon.

The reason for Boyce's falling out was that Potchen, who is former Military Intelligence, had been making modifications to the hydroxy-generating device that Boyce said were reducing the cell's efficiency. Prior to those modifications, the cell was producing great results when installed in test vehicles. In one case, the mileage of a truck increased from 5.5 mpg to 11.7 mpg – more than double.

Boyce described a number of modifications that Potchen made in the name of making the cell cheaper to produce, but which significantly worked against the efficiency. "It's as if he was intentionally sabotaging the system to discredit the field."

Boyce withdrew his endorsement of Potchen's device and published his concerns to some hydroxy forums.

The saga from there is long and drawn-out and still ongoing. This is the latest installation.

Ironically, Boyce's operation yesterday was exactly one year after we posted a story: [Boyce chip implanter suspect identified](#).

###

Photos

The chip photos were taken by the surgeon's staff. The VeriChip (called "foreign body" for political reasons) was removed from the tissue (made blue from the dyes used to identify cancerous tissue) and placed in a specimen container and sealed by the surgeon. Part of the problem with the fuzzy resolution is that these are photos of photos taken by the staff. Bob has these posted on his site at <http://www.bobbyboyce.org/cancer.htm>

I don't recommend looking at these photos while eating, which is what I was doing this afternoon when I first looked at them.

Bob sent this photo to me on Dec. 10, showing his stitches from the surgery. The redness ahead of the stitches on the right in the photo is from an allergic reaction Boyce had to the tape used to hold the bandage on.



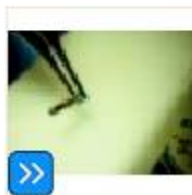
IM001967.jpg



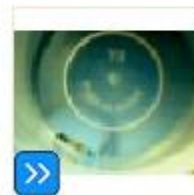IM001968.jpg



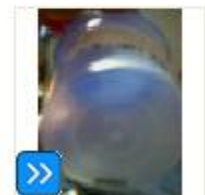IM001969.jpg



IM001970.jpg



IM001971.jpg



IM001972.jpg

Pathology/Radiology Reports from 2009

The pathology report from 2009 when Boyce had the VeriChip-induced tumor removed, along with the chip, didn't mention the foreign body. The radiology report on the right was from the X-rays that were taken when Boyce discovered that a second chip was still embedded in his shoulder.

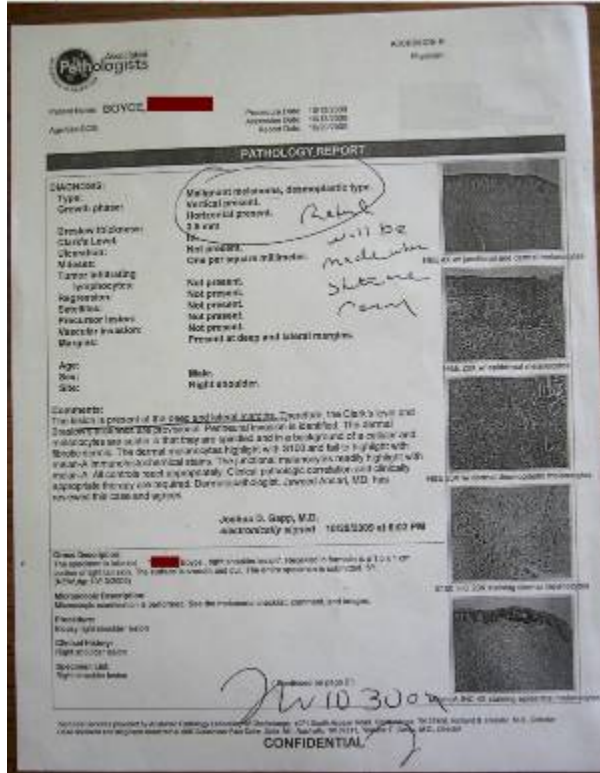
2009 Pathology Report

Click image to download larger version.

2009 Radiology Report

Click image to download larger version.

Bob Boyce' 2009 Pathology Report doesn't mention first foreign body.



Pathologists Associated...
Boyce...

Diagnosis: Malignant melanoma, desmoplastic type...
Right shoulder

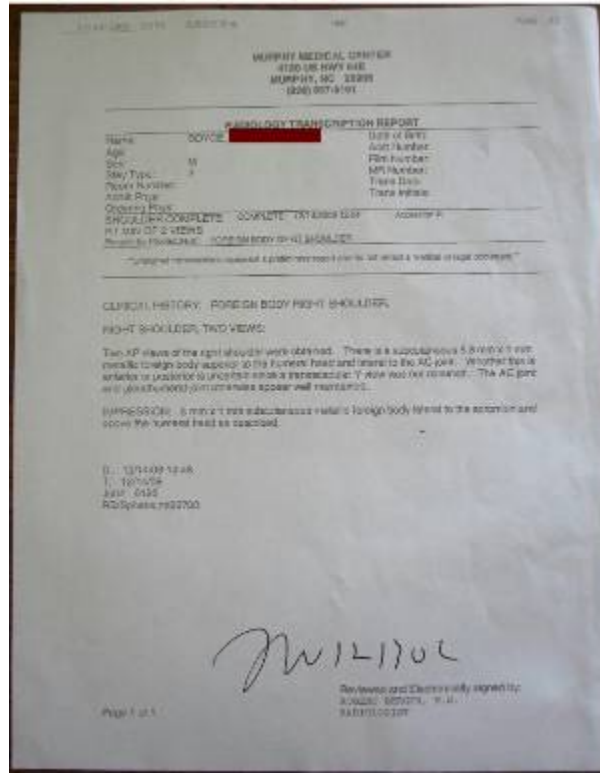
10/20/2009

Pathology Reports from 2010

On Dec. 21, 2010, Bob let me know that he got his pathology report back, and that the prognosis is good for the tumor. There was no cancer detected in the margins of the excised tumor, and no cancer was founded in the surrounding lymph nodes.

- [Surgeon's Operative Report, p. 1](#) "Preoperative Diagnosis: Melanoma and foreign body, right shoulder"
"Postoperative Diagnosis: Melanoma and foreign body, right shoulder"
"Procedure: ...3 Removal of foreign body, right shoulder"
"Surgeon: Tiomothy Whitaker, MD; Assistant: John Stafford, FNP-C"
"Indications: He had undergone biopsies of this region of pathology confirmation. He also had a foreign body noted in the right shoulder on a x-ray."
"Pathologic Findings: ...Foreign body was a glass encapsulated device with Copper coated wire wound within the device and was felt to be consistent with some sort of microprocessor." (Timothy Whitaker, MD; 12/6/2010)
- [Surgeon's Operative Report, p. 2](#) "...The specimen was placed under fluoroscopy and foreign body was noted to be within the specimen..... Attention was then turned to the specimen which was excised from posterior standpoint, and

Bob Boyce' 2009 Radiological Report of foreign body.



Murphy Medical Center...
Boyce...

CLINICAL HISTORY: FOREIGN BODY RIGHT
SHOULDER

RIGHT SHOULDER, TWO VIEWS:

Two AP views of the right shoulder were obtained. There is a subcutaneous 5.3 mm x 1 mm metallic foreign body superior to the humeral head and lateral to the AC joint....

D: 12/14/09 13:48

the glass encapsulated foreign body metallic processor appearing object was removed. This was sealed in a container and given to the patient postoperatively...." (Timothy Whitaker, MD; 12/6/2010)

- [December 16 2010 Pathology Report, Page 1](#)
- [December 16 2010 Pathology Report, Page 2](#) "Clinical History: Melanoma right shoulder. Foreign body right shoulder. (Foreign body to patient.)"
- [December 16 2010 Pathology Report, Page 3](#)

Comments

Surgeons Willing to Remove Such Chips are Hard to Find

On December 10, 2010 11:17 AM MST, Dr. John Hall wrote:

I recently read your article about the inventor from Georgia, Mr. Bob Boyce. I am a medical doctor in Texas specializing in anesthesia and pain management. I am the author of, *A New Breed: Satellite Terrorism in America* and host a website at www.satweapons.com.

Over the past ten years I have dealt with many patients from here and other states suspecting covert chipping. The topic of my book is the struggle of a former patient and ex-fiancé who was victimized by a PI group utilizing advanced surveillance methods. I have since become an activist against non-consensual experimentation and have found implants in several individuals who have sent me their scans. This is a growing national problem that has received very little attention from the mainstream media. A great majority of these patients are labeled as delusional and further victimized by the medical community, largely ignorant of advances in surveillance technology.

I would be very interested in speaking with Mr. Boyce to find out what surgeon was willing to perform his excision. Patients in whom we have identified implants are having trouble finding surgeons willing to remove them, often resorting to fabrication of an incident in order to even get an X-ray or MRI to find them, much less have them excised. If you are allowed, please forward my email and email address to him. He may be of a great assistance to others with similar problems. Thank you for your time.

Sterling responded:

You should be aware of Dr. Roger Leir, who specializes in removing chips implanted by aliens. He was interviewed on Coast to Coast AM on November 5, 2010. <http://www.coasttocoastam.com/show/2010/11/05>

I called in that night, after that interview, having done a story that day about a couple of the other guests on that show: http://pesn.com/2010/11/06/9501720_Colbern_confirms_Hutchison_frequency_generator_effects/

* * * *